

Table S1 Scoring system for calculating a disease activity index

	Weight loss (%)	Stool consistency	rectal bleeding
0	None	Normal	Negative
1	1-5%	Mild soft stool	weakly positive
2	5-10%	Sever soft stool	positive
3	10-20%	Mild diarrhea	intensely positive
4	>20%	Severe diarrhea	Gross blood

Table S2 Score of inflammation-associated histological changes in colon

score	Inflam- mation	Lesions Depth	Crypt Destruction	Lesions Width
0	none	none	none	0
1	mild	Submucosa	1/3 basal crypt	1-25
2	Severe	Muscularis	2/3 basal crypt	26-50
3	-	Sera	Intact epithelium only	51-75
4	-	-	Total crypt and epithelium	76-100

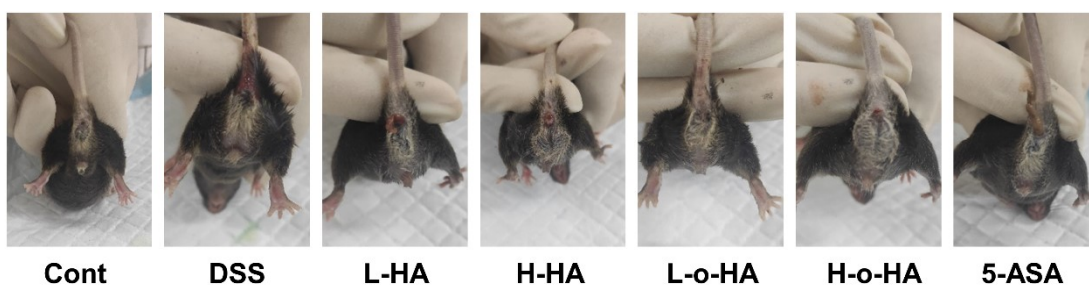


Fig.S1 Representative macroscopic appearances of hematochezia and diarrhea

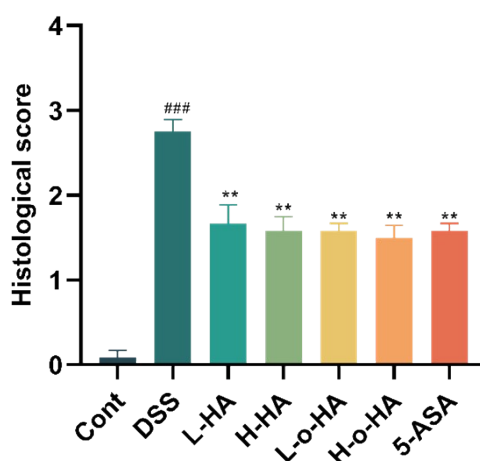


Fig. S2 Histological score

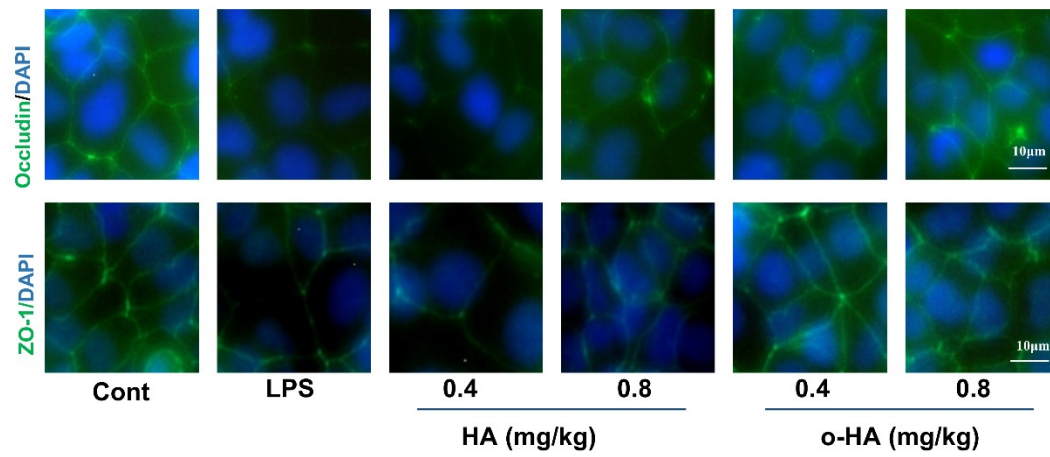


Fig.S3 Expression of ZO-1 and occludin was evaluated by immunofluorescence. The nucleus was stained with DAPI (blue).